

Dermacentor*-borne Necrosis Erythema and Lymphadenopathy (DEBONEL): A Case Associated with *Rickettsia rioja

Lidia Pérez-Pérez¹, Aránzazu Portillo², Francisco Allegue¹, Ander Zulaica¹, José A. Oteo², José-Luis Caeiro¹ and José-Maria Fabeiro¹

¹Department of Dermatology, Complejo Hospitalario Universitario de Vigo, C/ Porriño 5, ES-36209 Vigo and ²Hospital San Pedro-Centro de Investigación Biomédica de La Rioja (CIBIR), Centro de Rickettsiosis y Enfermedades Transmitidas por Artrópodos Vectores, Logroño, Spain. E-mail: lidiacomba@yahoo.es

Accepted October 22, 2009.

Sir,

Ticks are widely distributed haematophagus ectoparasites and have become one of the most important vectors of human pathogens worldwide. In Europe they transmit more vector-borne diseases to humans than any other agent (1). Not only bacteria, but also viruses, protozoa and neurotoxins, can be transmitted to humans by ticks, causing a wide number of infections, which include tick-borne rickettsiosis, anaplasmosis, relapsing fever, tularemia, tick-borne encephalitis, erlichiosis, borreliosis and tick-borne babesiosis (2).

DEBONEL is the acronym for *DErmacentor*-*BO*rne *N*ecrosis *E*rythema and *L*ymphadenopathy, which was coined in Spain by Oteo et al. (3) as an alternative term to the nomenclature TIBOLA (T*ick*-*BO*rne *L*ymph*A*d*e*no*p*athy) (4). It shows particular epidemiological, clinical and microbiological characteristics, and is therefore considered as a different entity among the rickettsioses group. Being aware of its main features will probably influence the reporting of a growing number of new cases.

CASE REPORT

An otherwise healthy 55-year-old woman was referred to our clinic by her general practitioner in February 2009 for assessment of an "infected cyst" on her scalp. She had been walking in the countryside (Ganfei, North Portugal) 10 days previously. The clinical examination revealed a tick attached to her scalp on her left parieto-temporal region surrounded by an erythematous area (Figs 1A–B). Some painful lymphadenopathies were identified in her left retroauricular and cervical regions. The patient also reported intense headache and slight malaise. No other systemic symptoms were recorded. Doxycycline (100 mg twice a day for 14 days) was started, with progressive resolution of headache and lymphadenopathies; however a painful necrotic eschar measuring 12 mm with an erythematous halo (Fig. 2A)

was evident at the bite site 2 weeks later. Secondary alopecia on the affected site (Fig. 2B) was observed 1.5 months after the tick bite. Blood examination (including blood cell count and biochemistry) was ordered, only yielding a slight elevation of C-reactive protein and erythrocyte sedimentation rate levels. The tick was identified as an adult female specimen of *Dermacentor marginatus*. Candidatus *Rickettsia rioja* was identified in our tick sample by polymerase chain reaction (PCR) and sequencing of partial *ompA* gene (Fig. 3). Indirect immunofluorescence assays (IFA) for the presence of IgG antibodies against *R. conorii* and *R. typhi* were negative.

DISCUSSION

DEBONEL is a recently described emergent disease classified among the spotted fever group rickettsioses. The first case was reported in a 39-year-old woman in 1997 by Raoult et al. (5), and the causative agent was demonstrated in 2003 when Cazorla et al. (6) cultured *R. slovacica* culprit.

DEBONEL is mainly caused by *R. slovacica* (7). However, the possible role of other *Rickettsia* spp., which show highest similarity with RpA4, DnS14 and DnS28 (genotypes now grouped as *R. raoultii*), in the development of DEBONEL has been suggested (8–10). Candidatus *R. rioja* is a novel rickettsial species, identified recently in Spanish patients, including ours. Genetic characterization of *ompA*, *ompB* and *gltA* genes from this proposed species has been performed recently in Spain by Portillo et al. (11).

DEBONEL is transmitted by ticks of the genus *Dermacentor*. *D. marginatus* Sulzer 1776 is the most frequently identified species, although *D. reticulatus* has been involved in some cases (12). *Dermacentor* ticks show particular parasitic habits: they show their

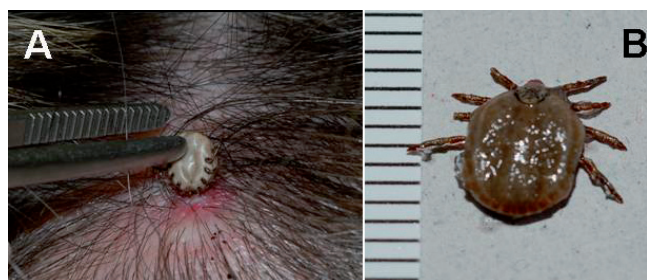

Fig. 1. (A) A tick attached to the patient's scalp, with an erythematous area on the bite site. (B) Adult female *Dermacentor marginatus*, extracted from the patient. (Scale in mm.)

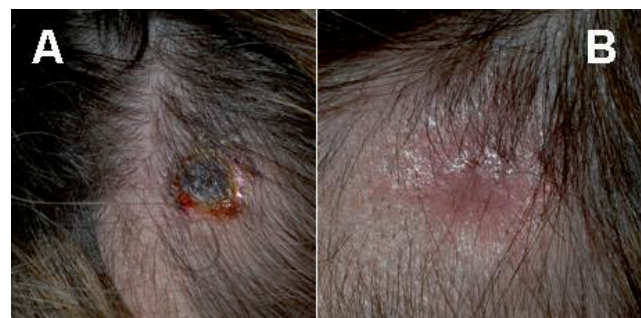

Fig. 2. (A) Necrotic eschar measuring 12 mm with an erythematous halo on the patient's scalp. (B) Secondary alopecia at the tick bite site.

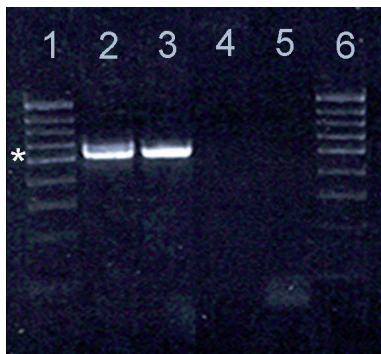


Fig. 3. Verification of PCR products obtained from the patient's tick. Lanes 1 and 6: ladder (*532 bp); lane 2: positive control: *Rickettsia conorii*; lane 3: our PCR product; lane 4: negative control (no primers); lane 5: negative control (no DNA).

maximal activity during the cold months of the year, usually wait for a host in 1.5 m high vegetation and feed on hairy animals (12). These two latter characteristics might explain the predilection *D. marginatus* shows for biting the heads of women and children (12).

After a variable incubation period (mean 4–5 days), a necrotic eschar with a peripheral erythema appears, the head being the commonest reported location (3). Other cutaneous manifestations are not seen, contrary to what is the rule in other rickettsioses (i.e. Mediterranean spotted fever). An intense headache is very frequent, mainly if the bite is located on the head (9). Fever, fatigue, dizziness, sweating, myalgia, arthralgia and loss of appetite have also been reported (13). Secondary persistent or transitory alopecia at the site of the tick bite and persistent asthenia for up to 3 months are the only sequelae recorded (12). Blood cell count and blood biochemistry have revealed elevated erythrocyte sedimentation rates and white cell counts, mild leucopaenia, monocytosis, thrombocytopenia and increased transaminase levels in some patients (14).

PCR of biological samples extracted from the tick or the patient (serum, blood, lymphadenopathy aspirate, skin biopsy) is the most specific test to confirm DEBONEL (12). Serological testing presents some important limitations: it is insensitive (12), partially due to the fact that DEBONEL is a localized disease, titres tend to be low and there are frequently cross-reactions with other *Rickettsiae* of the spotted fever group (6). Culture of *Rickettsia* is difficult and is performed only in laboratories with special security measures.

Early treatment appears to shorten the course of the disease and to induce rapid remission of the symptoms (3). Different antibiotic regimens have been used (15), doxycycline (100 mg twice a day for 10–14 days) being the most widely administered. Josamycin (500 mg twice a day, for 14 days) and azithromycin (10 mg/kg/day, for 5 days) are safe alternatives in children and pregnant

women. Fluoroquinolones and chloramphenicol have also been suggested (7)

We consider this report to be of relevance to dermatologists, because DEBONEL has rarely been reported in the dermatological literature and may therefore be a little-known disease among dermatologists. Moreover, our report provides new evidence to support the role of other rickettsial species in the development of DEBONEL.

REFERENCES

- Anderson JF. The natural history of ticks. *Med Clin North Am* 2002; 86: 205–218.
- Bitam I, Raoult D. Other tick-borne diseases in Europe. *Curr Probl Dermatol* 2009; 37: 130–154.
- Oteo JA, Ibarra V, Blanco J. Eritema, necrosis y linfadenopatía. Una nueva enfermedad (DEBONEL) transmitida por *Dermacentor marginatus* Sulzer 1776. *Zubia Monogr* 2000; 12: 49–58.
- Lakos A. Tick-borne lymphadenopathy – a new rickettsial disease? *Lancet* 1997; 350: 1006.
- Raoult D, Berbis Ph, Roux V, Xu W, Maurin M. A new tick-transmitted disease due to *Rickettsia slovaca*. *Lancet* 1997; 12: 112–113.
- Cazorla C, Enea M, Lucht F, Raoult D. First isolation of *Rickettsia slovaca* from a patient, France. *Emerg Infect Dis* 2003; 9: 135.
- Sekeyova Z, Roux V, Xu W, Rehacek J, Raoult D. *Rickettsia slovaca* sp nov, a member of the spotted fever group rickettsiae. *Int J Syst Bacteriol* 1998; 48: 1455–1462.
- Ibarra V, Portillo A, Santibáñez S, Blanco JR, Pérez-Martínez L, Márquez J, et al. DEBONEL/TIBOLA. Is *Rickettsia slovaca* the only etiological agent? *Ann NY Acad Sci* 2005; 1063: 346–348.
- Oteo JA, Ibarra V, Blanco JR, Martínez de Artola V, Márquez FJ, Portillo A, et al. *Dermacentor*-borne necrosis erythema and lymphadenopathy: clinical and epidemiological features of a new tick-borne disease. *Clin Microbiol Infect* 2004; 10: 327–331.
- Mediannikov O, Matsumoto K, Samoylenko I, Drancourt M, Roux V, Rydkina E, et al. *Rickettsia raoultii* sp. nov., a spotted fever group rickettsia associated with *Dermacentor* ticks in Europe and Russia. *Int J Syst Evol Microbiol* 2008; 58: 1635–1639.
- Portillo A, Ibarra V, Santibáñez S, Pérez-Martínez L, Blanco JR, Oteo JA. Genetic characterisation of *ompA*, *ompB* and *gltA* genes from *Candidatus Rickettsia rioja*. *Clin Microbiol Infect* 2009; [Epub ahead of print].
- Raoult D, Lakos A, Fenollar F, Beytout J, Brouqui P, Fournier PE. Spotless rickettsiosis caused by *Rickettsia slovaca* and associated with *Dermacentor* ticks. *Clin Infect Dis* 2002; 34: 1331–1336.
- Lledó L, Gegúndez MI, Fernandes N, Sousa R, Vicente J, Alamo R, et al. The seroprevalence of human infection with *Rickettsia slovaca*, in an area of northern Spain. *Ann Trop Med Parasitol* 2006; 100: 337–343.
- Lakos A. Tick-borne lymphadenopathy (TIBOLA). *Wien Klin Wochenschr* 2002; 114: 648–654.
- Ibarra V, Blanco JR, Portillo A, Santibáñez S, Metola L, Oteo JA. Effect of antibiotic treatment in patients with DEBONEL/TIBOLA. *Ann N Y Acad Sci* 2005; 1063: 257–258.